

---

## Tissue System in Animals

### Objectives

After going through this lesson, the learners learn the following concepts:

- Animal Tissues
- Epithelial Tissue
- Connective Tissue
- Muscular Tissue
- Neural Tissue

### Content Outline

- Introduction
- Animal Tissues
  - Epithelial Tissue
  - Connective Tissue
  - Muscular Tissue
  - Neural Tissue
- Summary

### Introduction

In unicellular organisms, all functions like digestion, respiration and reproduction are performed by a single cell. In the complex body of multicellular animals the same basic functions are carried out by different groups of cells in a well organised manner. The body of a simple organism like *Hydra* is made of different types of cells and the number of cells in each type can be in thousands. The human body is composed of billions of cells to perform various functions. How do these cells in the body work together? In multicellular animals, a group of similar cells along with intercellular substances perform a specific function. Such an organization is called **tissue**. The branch of science that deals with the study of tissues is called Histology.

You may be surprised to know that all complex animals consist of only four basic types of tissues. These tissues are organised in specific proportion and pattern to form an organ like stomach, lung, heart and kidney. When two or more organs perform a common function by their physical and/or chemical interaction, they together form an organ system, e.g., digestive

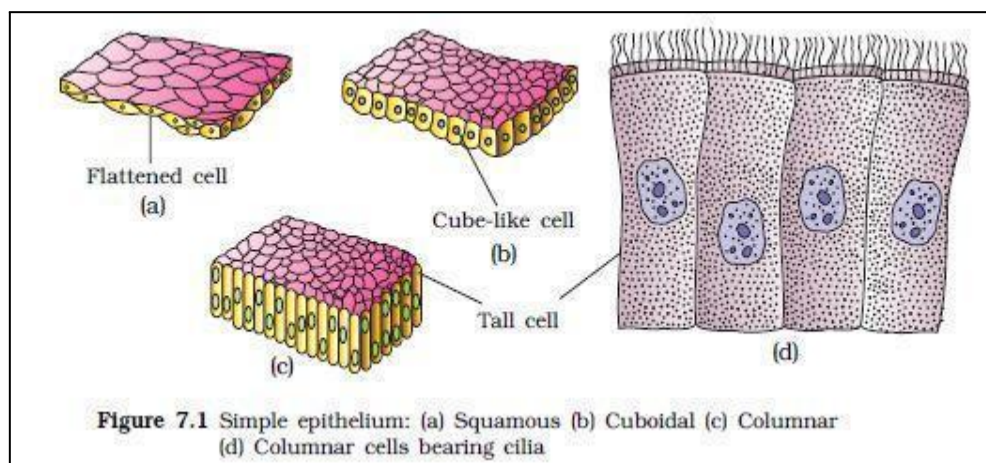
system, respiratory system, etc. Cells, tissues, organs and organ systems split up the work in a way that exhibits division of labour and contribute to the survival of the body as a whole.

## Animal Tissues

The structure of the cells varies according to their function. Therefore, the tissues are different and are broadly classified into four types: (i) Epithelial (ii) Connective (iii) Muscular and (iv) Neural

### Epithelial Tissue

We commonly refer to an epithelial tissue as epithelium (pl.: epithelia). Epithelial tissue is



made of closely-packed cells arranged in flat sheets. Epithelia form the surface of the skin, line the various cavities and tubes of the body, and cover the internal organs. This tissue has a free surface, which faces either a body fluid or the outside environment and thus provides a covering or a lining for some part of the body. The cells are compactly packed with little intercellular matrix. There are two types of epithelial tissues namely **simple epithelium** and **compound epithelium**. Simple epithelium is composed of a single layer of cells and functions as a lining for body cavities, ducts, and tubes. The compound epithelium consists of two or more cell layers and has protective function as it does in our skin.

**Simple epithelium:** on the basis of structural modification of the cells, simple epithelium is further divided into three types. These are (i) Squamous, (ii) Cuboidal, (iii) Columnar.

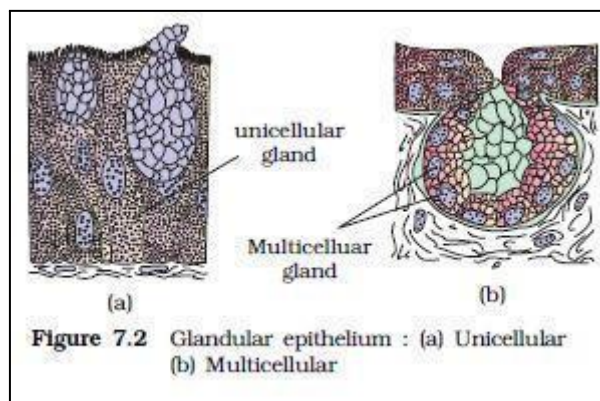
- The **squamous epithelium** is made of a single thin layer of flattened cells with irregular boundaries. They are found in the walls of blood vessels and air sacs of lungs and are involved in functions like forming a diffusion boundary. The edges of the squamous cells are irregular and there are special junctions between neighbouring cells which help to bind them firmly together. These are present in areas such as renal

---

capsules of the kidney, the alveoli of the lungs and walls of the blood capillaries. It is also present in the hollow linings of the blood vessels and heart chambers to allow frictionless flow of fluids.

- The **cuboidal epithelium** is composed of a single layer of cube-like cells. This is commonly found in ducts of glands and tubular parts of nephrons in kidneys and its main functions are secretion and absorption. The epithelium of proximal convoluted tubule (PCT) of nephron in the kidney has microvilli.
- The **columnar epithelium** is composed of a single layer of tall and slender cells. Their nuclei are located at the base. Free surface may have microvilli. They are found in the lining of stomach and intestine and help in secretion and absorption. If the columnar or cuboidal cells bear cilia on their free surface they are called **ciliated epithelium** (Figure 7.1d). Their function is to move particles or mucus in a specific direction over the epithelium. They are mainly present in the inner surface of hollow organs like bronchioles and fallopian tubes.

Some of the columnar or cuboidal cells get specialised for secretion and are called **glandular epithelium** (Figure 7.2).

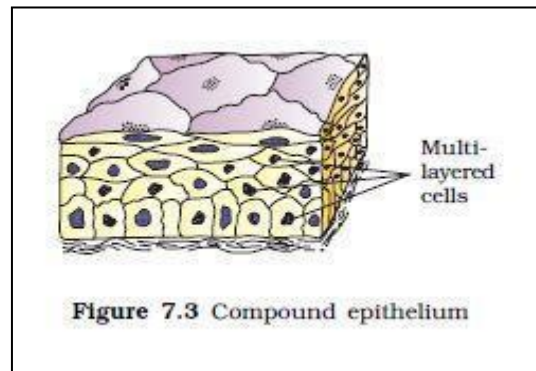


They are mainly of two types: unicellular, consisting of isolated glandular cells (goblet cells of the alimentary canal), and multicellular, consisting of clusters of cells (salivary gland). On the basis of the mode of pouring of their secretions, glands are divided into two categories namely **exocrine** and **endocrine** glands. Exocrine glands secrete mucus, saliva, earwax, oil, milk, digestive enzymes and other cell products. These products are released through ducts or tubes. In contrast, endocrine glands do not have ducts. Their products called hormones are secreted directly into the fluid bathing the gland.

- **Compound epithelium** is made of more than one layer (multi-layered) of cells and thus has a limited role in secretion and absorption (Figure 7.3). Their main function is to provide protection against chemical and mechanical stresses. They cover the dry surface

---

of the skin, the moist surface of buccal cavity, pharynx, inner lining of ducts of salivary glands and of pancreatic ducts.



All cells in epithelium are held together with little intercellular material. In nearly all animal tissues, specialised junctions provide both structural and functional links between its individual cells. Three types of cell junctions are found in the epithelium and other tissues. These are called tight, adhering and gap junctions. **Tight junctions** help to stop substances from leaking across a tissue. **Adhering junctions** perform cementing to keep neighbouring cells together. **Gap junctions** facilitate the cells to communicate with each other by connecting the cytoplasm of adjoining cells, for rapid transfer of ions, small molecules and sometimes big molecules.

Some of the functions of the epithelial tissues are:

- The epithelium of the skin protects the underlying tissues from
  - mechanical damage
  - ultraviolet light
  - dehydration
  - invasion by bacteria
- The columnar epithelium of the intestine
  - secretes digestive enzymes into the intestine;
  - absorbs the products of digestion from it.
- Epithelium also lines the air passages and the alveoli of the lungs. It secretes mucus which keeps it from drying out and traps inhaled dust particles. Most of its cells have cilia on their apical surface that propel the mucus with its load of foreign matter back up to the throat.

For better understanding of the Epithelial tissues see the following table:

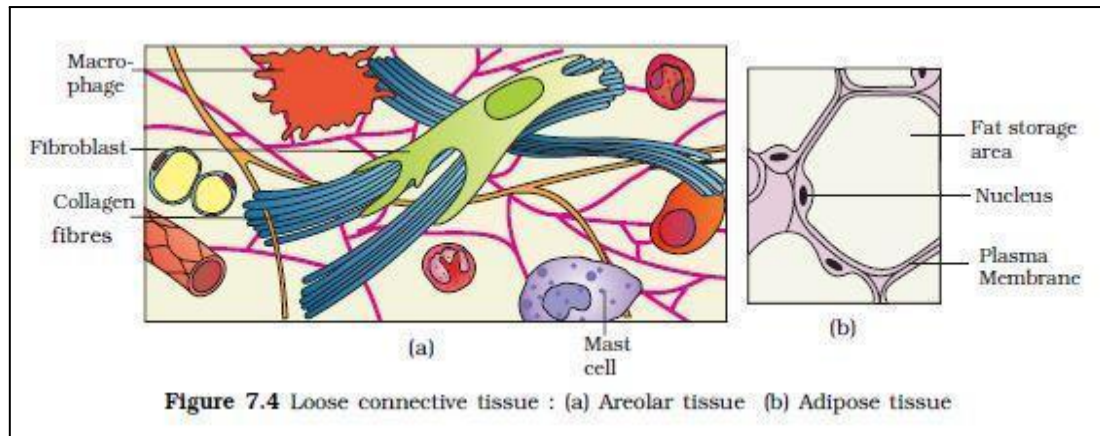
Covering and Lining Epithelial Tissue	Types of Epithelial Tissue (in this classification)
<u>Classification by Cell Shape:</u> <ul style="list-style-type: none"> <li>• Squamous</li> <li>• Cuboidal</li> <li>• Columnar</li> <li>• Transitional</li> </ul>	
<u>Classification by Arrangement of Layers:</u> <ul style="list-style-type: none"> <li>• Simple Epithelium</li> <li>• Stratified Epithelium</li> <li>• Pseudostratified columnar Epithelium</li> </ul>	<ul style="list-style-type: none"> <li>• Simple squamous epithelium</li> <li>• Simple cuboidal epithelium</li> <li>• Nonciliated simple columnar epithelium</li> <li>• Ciliated simple columnar epithelium</li> <li>• Stratified squamous epithelium</li> <li>• Stratified cuboidal epithelium</li> <li>• Stratified columnar epithelium</li> <li>• Transitional epithelium</li> <li>• Pseudostratified columnar epithelium.</li> </ul>
<b>Glandular Epithelial Tissue</b> <ul style="list-style-type: none"> <li>• Endocrine Glands</li> <li>• Exocrine Glands</li> </ul>	<ul style="list-style-type: none"> <li>• (Tissue of) Endocrine Glands</li> <li>• (Tissue of) Exocrine Glands</li> </ul>

Source: [http://www.ivyroses.com/HumanBody/Tissue/Tissue\\_4-Tissue-Types.php](http://www.ivyroses.com/HumanBody/Tissue/Tissue_4-Tissue-Types.php)

Different Types of Epithelial Tissues and their location		
Cell Shape	Description	Location
Columnar	Tall, Narrow, nucleus toward base Tall, narrow, nucleus along cell	Simple: digestive tract Pseudostratified: respiratory tract
Cuboidal	Cube shaped, central nucleus	Glands, renal tubules
Squamous	Flat, irregular round shape	Simple: lung alveoli, capillaries stratified: skin, mouth, vagina
Transitional	Round, simple but appear stratified	Urinary bladder

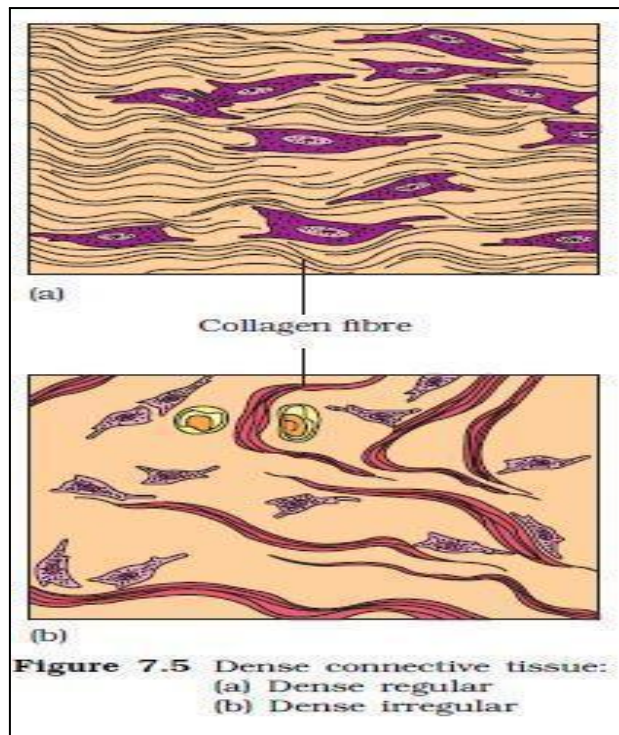
### Connective Tissue

Connective tissues are most abundant and widely distributed in the body of complex animals. They are named connective tissues because of their special function of linking and supporting other tissues/organs of the body. They range from soft connective tissues to specialised types, which include cartilage, bone, adipose, and blood. In all connective tissues except blood, the cells secrete fibres of structural proteins called collagen or elastin. The fibres provide strength, elasticity and flexibility to the tissue.



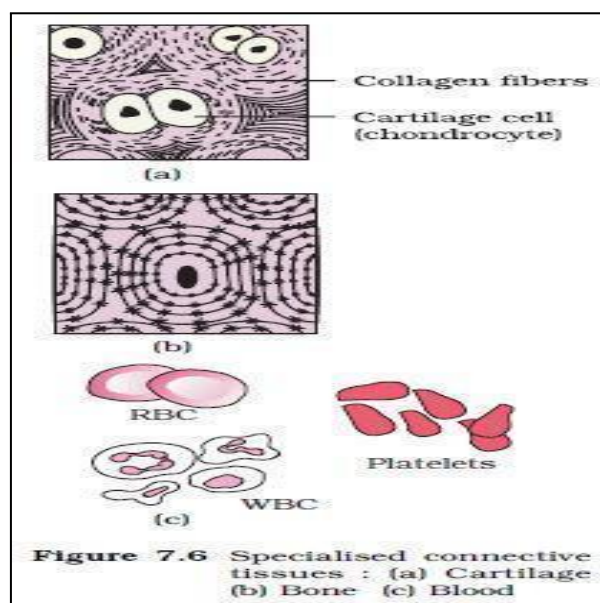
These cells also secrete modified polysaccharides, which accumulate between cells and fibres and act as matrix (ground substance). Connective tissues are classified into three types: (i) Loose connective tissue, (ii) Dense connective tissue and (iii) Specialised connective tissue.

- i) **Loose connective tissue** has cells and fibres loosely arranged in a semi-fluid ground substance, for example, **areolar tissue** present beneath the skin (Figure 7.4). Often it serves as a support framework for epithelium. It contains fibroblasts (cells that produce and secrete fibres), macrophages and mast cells. **Adipose tissue** is another type of loose connective tissue located mainly beneath the skin. The cells of this tissue are specialised to store fats. The excess of nutrients which are not used immediately are converted into fats and are stored in this tissue.
- ii) **Dense Connective tissue:** Fibres and fibroblasts are compactly packed in the **dense connective tissues**. Orientation of fibres show a regular or irregular pattern and are called **dense regular** and **dense irregular tissues**. In the dense regular connective tissues, the collagen fibres are present in rows between many parallel bundles of fibres. Tendons, which attach skeletal muscles to bones and ligaments which attach one bone to another are examples of this tissue. Dense irregular connective tissue has fibroblasts and many fibres (mostly collagen) that are oriented differently (Figure 7.5).



iii) **Specialised connective tissue:** This tissue is present in the skin. Cartilage, bones and blood are various types of **specialized connective tissues**.

The intercellular material of **cartilage** is solid and pliable and resists compression. Cells of this tissue (chondrocytes) are enclosed in small cavities within the matrix secreted by them (Figure 7.6a). Most of the cartilages in vertebrate embryos are replaced by bones in adults. Cartilage is present in the tip of nose, outer ear joints, between adjacent bones of the vertebral column, limbs and hands in adults.



**Bones** have a hard and non-pliable ground substance rich in calcium salts and collagen fibres which give bone its strength (Figure 7.6b). It is the main tissue that provides structural frame to the body. Bones support and protect softer tissues and organs. The bone cells (osteocytes) are present in the spaces called lacunae. Limb bones, such as the long bones of the legs, serve weight-bearing functions. They also interact with skeletal muscles attached to them to bring about movements. The bone marrow in some bones is the site of production of blood cells.

**Blood** is a fluid connective tissue containing plasma, red blood cells (RBC), white blood cells (WBC) and platelets (Figure 7.6c). It is the main circulating fluid that helps in the transport of various substances.

Connective Tissues			
Tissue	Cells	Fibers	Location
loose/areolar	fibroblasts, macrophages, some lymphocytes, some neutrophils	few: collagen, elastic, reticular	around blood vessels; anchors epithelia
dense, fibrous connective tissue	fibroblasts, macrophages,	mostly collagen	irregular: skin regular: tendons, ligaments
cartilage	chondrocytes, chondroblasts	hyaline: few collagen fibrocartilage: large amount of collagen	shark skeleton, fetal bones, human ears, intervertebral discs
bone	osteoblasts, osteocytes, osteoclasts	some: collagen, elastic	vertebrate skeletons
adipose	adipocytes	few	adipose (fat)
blood	red blood cells, white blood cells	none	blood



### Embryonic Connective Tissue

- Mesenchyme
- Mucous connective tissue

### Mature Connective Tissue

#### Loose Connective Tissue:

- Areolar Tissue
- Adipose Tissue
- Reticular Tissue

#### Dense Connective Tissue:

- Dense Regular Connective Tissue (*White Fibrous Tissue*)
- Dense Irregular Connective Tissue
- Elastic Connective Tissue (*Yellow Elastic Tissue*)

#### Cartilage Tissue:

- Hyaline Cartilage
- Fibrocartilage
- Elastic Cartilage

#### Bone (Osseous) Tissue:

- Compact Bone
- Spongy Bone

#### Blood Tissue:

- Erythrocytes
- Thrombocytes
- Leucocytes

#### Lymphatic Tissue:

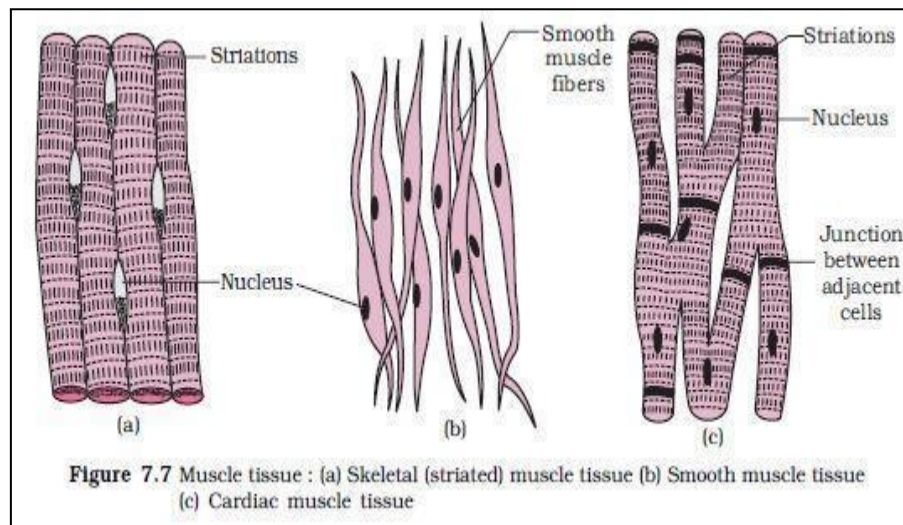
- Lymph

Source: [http://www.ivyroses.com/HumanBody/Tissue/Tissue\\_4-Tissue-Types.php](http://www.ivyroses.com/HumanBody/Tissue/Tissue_4-Tissue-Types.php)

### Muscle Tissue

Source: Each muscle is made of many long, cylindrical fibres arranged in parallel arrays. These fibres are composed of numerous fine fibrils, called myofibrils. Muscle fibres contract (shorten) in response to stimulation, then relax (lengthen) and return to their uncontracted state in a coordinated fashion. Their action moves the body to adjust to the changes in the environment and to maintain the positions of the various parts of the body. In general, muscles play an active role in all the movements of the body. Muscles are of three types, skeletal, smooth, and cardiac.

- i) **Skeletal muscle** tissue is closely attached to skeletal bones. In a typical muscle such as the biceps, striated (striped) skeletal muscle fibres are bundled together in a parallel fashion (Figure 7.7a). A sheath of tough connective tissue encloses several bundles of muscle fibres (You will learn more about this in Chapter 20).



- ii) The **smooth muscle** fibres taper at both ends (fusiform) and do not show striations (Figure 7.7b). Cell junctions hold them together and they are bundled together in a connective tissue sheath. The wall of internal organs such as the blood vessels, stomach and intestine contains this type of muscle tissue. Smooth muscles are involuntary as their functioning cannot be directly controlled. We usually are not able to make it contract merely by thinking about it as we can do with skeletal muscles.
- iii) **Cardiac muscle tissue** is a contractile tissue present only in the heart. Cell junctions fuse the plasma membranes of cardiac muscle cells and make them stick together (Figure 7.7c). Communication junctions (intercalated discs) at some fusion points allow the cells

Types of Muscles				
Type of Muscle	Striations	Nuclei	Control	Location
smooth	no	single, in center	involuntary	visceral organs
skeletal	yes	many, at periphery	voluntary	skeletal muscles
cardiac	yes	single, in center	involuntary	heart

to contract as a unit, i.e., when one cell receives a signal to contract, its neighbours are also stimulated to contract.

<b>Skeletal Muscle (Tissue):</b>	located throughout the body and under conscious (i.e. "voluntary") control, main function movement of the structures of the body, and the body as a whole, e.g. by walking, running, etc..
<b>Cardiac Muscle (Tissue):</b>	which is found only in the heart and is important for effective blood-flow through the heart.
<b>Smooth Muscle (Tissue):</b>	involuntary muscle tissue located around the walls of many internal structures such as the stomach and intestines and important for aiding the passage of materials/fluids through those structures.

Source: [http://www.ivyroses.com/HumanBody/Tissue/Tissue\\_4-Tissue-Types.php](http://www.ivyroses.com/HumanBody/Tissue/Tissue_4-Tissue-Types.php)

## Neural Tissue

Neural tissue exerts the greatest control over the body is responsiveness to changing conditions. Neurons, the unit of the neural system, are excitable cells (Figure 7.8). The neuroglial cells which constitute the rest of the neural system protect and support neurons. Neuroglia make up more than one half the volume of neural tissue in our body.

When a neuron is suitably stimulated, an electrical disturbance is generated which swiftly travels along its plasma membrane. Arrival of the disturbance at the neuron's endings, or output zone, triggers events that may cause stimulation or inhibition of adjacent neurons and other cells.

<b>Nerve Cells</b> (also known as <b>Neurons</b> or <b>Neurones</b> ) -	whose purpose is to transmit (electrical) nerve impulses that move information around the body.
<b>Neuroglia</b> (also known as simply <b>Glia</b> ) -	which support and protect nerve cells, depending on the particular type of glia. Examples of types of glia include astrocytes, ependymal cells, microglial cells, oligodendrocytes and Schwann cells.

Source: [http://www.ivyroses.com/HumanBody/Tissue/Tissue\\_4-Tissue-Types.php](http://www.ivyroses.com/HumanBody/Tissue/Tissue_4-Tissue-Types.php)

## Summary

Animal tissues are grouped into four basic types: epithelial, connective, muscle and nervous. Collections of tissues joined in structural units to serve a common function of composing organs. While all animals can generally be considered to contain the four tissue types, the manifestation of these tissues can differ depending on the type of organism. For example, the origin of the cells comprising a particular tissue type may differ developmentally for different classifications of animals.

## Some of the relevant terms in Histology

**Cartilage:** type of connective tissue with a large amount of ground substance matrix, cells called chondrocytes, and some amount of fibers.

---

**Chondrocyte:** cell found in cartilage.

**Columnar epithelia:** epithelia made of cells taller than they are wide, specialized in absorption.

**Connective tissue:** type of tissue made of cells, ground substance matrix, and fibers.

**Cuboidal epithelia:** epithelia made of cube-shaped cells, specialized in glandular functions.

**Dorsal cavity:** body cavity on the posterior or back portion of an animal; includes the cranial and vertebral cavities.

**Ectotherm:** animal incapable of maintaining a relatively constant internal body temperature.

**Endotherm:** animal capable of maintaining a relatively constant internal body temperature.

**Epithelial tissue:** tissue that either lines or covers organs or other tissues.

**Estivation:** torpor in response to extremely high temperatures and low water availability.

**Fibrous connective tissue:** type of connective tissue with a high concentration of fibers.

**Hibernation:** torpor over a long period of time, such as a winter.

**Homeostasis:** dynamic equilibrium maintaining appropriate body functions.

**Lacuna:** space in cartilage and bone that contains living cells.

**Matrix:** component of connective tissue made of both living and non-living (ground substances) cells.

**Negative feedback loop:** feedback to a control mechanism that increases or decreases a stimulus instead of maintaining it.

**Osteon:** subunit of compact bone.

**Positive feedback loop:** feedback to a control mechanism that continues the direction of a stimulus.

**Pseudostratified:** layer of epithelia that appears multilayered, but is a simple covering

**Set point:** midpoint or target point in homeostasis.

**Simple epithelia:** single layer of epithelial cells.

**Squamous epithelia:** type of epithelia made of flat cells, specialized in aiding diffusion or preventing abrasion.

**Stratified epithelia:** multiple layers of epithelial cells.

**Torpor:** decrease in activity and metabolism that allows an animal to survive adverse conditions.

**Trabecula:** tiny plate that makes up spongy bone and gives it strength.